

# Brain Trust

## Eisenhower Neurosurgeon Treats Complex Brain Tumor and Helps Patient Reclaim His Life

By: Roxanne Jones

In late 2009, then 66-year-old William Lopez did what he characterizes as a back flip on the ice in front of his Athol, Idaho home, hitting his head when he landed.

"I was out for maybe half a minute," Lopez recalls. "I made it through Christmas, but then I started having headaches."

Fearing that Lopez had suffered a concussion, his wife convinced him to see his doctor. Upon hearing about the fall and subsequent headaches, the doctor ordered a CT scan.

While there was no concussion, the scan did reveal a golf ball-sized tumor behind his left eye, surrounded by a fluid sac — produced by the tumor — making the entire mass the size of a baseball. Lopez's doctor referred him to a neurosurgeon in Coeur d'Alene for a consultation.

"The neurosurgeon said he wanted me to come back in about three weeks for a biopsy," Lopez says. "He wanted me to get over the headaches first, so I figured the situation wasn't that bad."

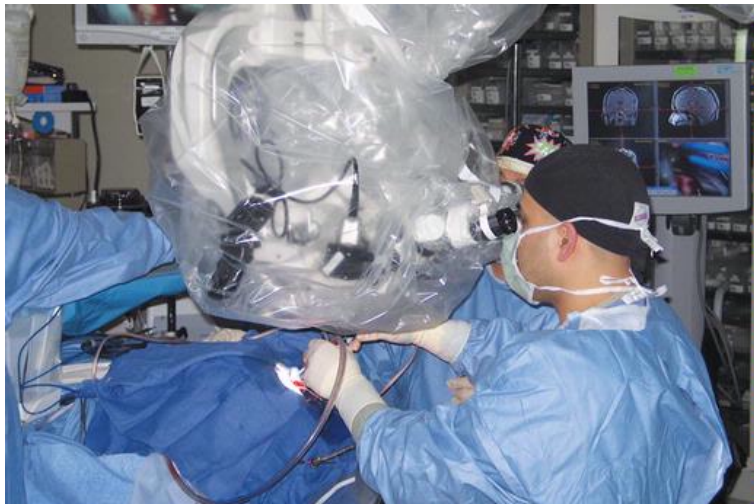
"He did the [biopsy] operation by opening up an area about the size of a silver dollar on my left temple," Lopez continues. "The nurse told me afterward that when she looked in there it was like looking into an aquarium — that there was nothing inside but fluid. That fluid sac had pushed my brain back."

The displacement of his brain by the tumor and surrounding fluid had also been affecting his behavior. In the months preceding Lopez's fall, this normally easy-going man had begun having emotional outbursts, according to his daughter Susan Effinger, RN, MSN/MHA, Director, Neurological Care Unit, Eisenhower Medical Center.

"His wife had called me to relate his bizarre behavior, how he was acting drunk but hadn't been drinking," Effinger says. "She was getting to the end of her rope."

"But then we learned about the tumor and how it was pushing up against his frontal lobe," Effinger explains, referring to the part of the brain that controls personality, among other things. "That's why he was exhibiting such significant behavioral changes."

Effinger and Lopez agree that his fall on the ice was a fortuitous accident since it enabled the discovery of the tumor.



Dr. Limonadi removes an encapsulated brain tumor in patient William Lopez.

The biopsy was performed in January of 2010 and revealed that, fortunately, the tumor — called a meningioma — was not cancerous. During the biopsy, the neurosurgeon also drained some of the fluid surrounding the tumor. A second surgery to remove the remainder of the fluid sac and the tumor itself was scheduled for within a few weeks.

During the second surgery, the neurosurgeon once again accessed Lopez's brain through a hole in his temple. He was able to remove the remaining fluid, which relieved some of the pressure on Lopez's brain and resolved many of his behavioral symptoms. But removing the tumor presented a problem.

"The surgeon said it was 'beyond his pay grade.' There were too many blood vessels involved for him to safely remove it through the hole in my temple," Lopez relates. "He felt that if the tumor didn't do anything, we could just leave it alone. But he recommended that I be monitored regularly and, if it started to grow, then he'd refer me to a specialist."

Lopez began a regimen of having an MRI exam every three months. After about a year, the scan revealed that his tumor had begun to grow.

In the meantime, Effinger had shown her father's scans to Eisenhower Neuroscience Institute Neurosurgeon Farhad Limonadi, MD.

"My daughter told the Idaho doctors that if I had to have another surgery, I was coming to Eisenhower," Lopez says. "They all thought that was a good idea."

In the spring of 2011, Lopez and his wife came to the desert so he could undergo pre-operative testing in advance of his brain surgery.

"The neurosurgeon who had tried to resect Mr. Lopez's tumor was extremely wise not to proceed," Dr. Limonadi says. "When I looked at the MRI, I could see the tumor had encapsulated (wrapped around) critical structures including the carotid artery, middle cerebral artery and the optic nerve. It was also in proximity to the dominant hemisphere of Mr. Lopez's brain, which controlled speech. Removing this tumor presented major challenges."

The optic nerve, Dr. Limonadi explains, is extremely fragile and unforgiving; the slightest injury to the microvessels that supply its blood could result in nerve damage and vision loss. What's more, damage to the carotid artery, middle cerebral artery or the brain itself could cause paralysis, the loss of expressive speech or the inability to understand speech. There was also the risk of death.

"But Mr. Lopez's major concern was whether after the operation he could use his left eye to shoot," Dr. Limonadi says, noting that his patient is left-side dominant. "He was an avid marksman and rifle and handgun precision-shooting enthusiast. It mattered to him that he could continue to shoot recreationally and precisely, so it was critical to preserve his vision."

"It was a concern I could fully share because I also enjoy marksmanship and precision shooting," Dr. Limonadi adds.

While removing the tumor posed some daunting challenges, it was certainly not beyond Dr. Limonadi's expertise. "He's brilliant," Effinger says. "And he specializes in the frontal approach, which was perfect for dad's tumor."

This frontal, or orbitozygomatic, approach entails removing the bones that surround the front of the eye in one piece, pushing the eyeball down in its socket, and accessing the tumor through the orbital roof.

"It affords me a panoramic view of the temporal and frontal lobes of the brain, which allows me to approach the tumor from a wide angle, without much manipulation of the brain tissue," Dr. Limonadi explains. "This helps to maintain the brain, untouched and safe."

This technique is also referred to as skull-base surgery, and Dr. Limonadi is the only neurosurgeon in his practice to perform it.

Dr. Limonadi also utilized cerebral angiography — an advanced imaging technology — to visualize the blood vessels that were supplying the tumor.

"By having a map of the vascular supply, I could approach it systematically," he explains. "I could remove the dominant vessel supplying the tumor while minimizing blood loss and injury to critical structures in the brain."

Before Dr. Limonadi could perform the surgery, however, Lopez's pre-op lab work revealed a problem. He had a condition called idiopathic thrombocytopenic purpura (ITP), a bleeding disorder in which the immune system destroys platelets, which are necessary for normal blood clotting.

"My father had one-third the number of platelets he should have had," Effinger says. "This posed a big problem for any type of surgery, especially brain surgery."

Under the supervision of Davood Vafai, MD, Board Certified in Internal Medicine/Medical Oncology, Lopez received special medication to boost his platelet-producing cells. By late May, his numbers were high enough for his surgery to proceed safely.

Dr. Limonadi used a surgical microscope, state-of-the-art computer navigation and stereotaxy to help guide him during the operation. Stereotaxy refers to medical imaging that precisely locates, in three dimensions, specific points within the brain. "I was able to map important structures in the brain to within less than two millimeters," he notes.

He also utilized intraoperative neurophysiological monitoring, which records electrical signals from the nervous system during surgery. This technology helps detect any injuries to the brain before they can cause deficits that could linger after the operation.

"Dr. Limonadi is so detail oriented and particular, making sure everything is done right to ensure his patient has the very best outcome," Effinger says. "It's appropriate that he has an engineering degree (he received his undergraduate degree in electrical engineering) in addition to being a neurosurgeon; it makes sense when working with the brain and neuro-circuitry."

The procedure to remove Lopez's tumor took more than eight hours.

"I spent the first several hours dissecting the tumor around the optic nerve," Dr. Limonadi says. Then he freed the carotid and middle cerebral arteries from the tumor and, when they were safely preserved, used a device called the Cavitron Ultrasonic Surgical Aspirator® (CUSA) to remove the tumor. CUSA uses ultrasonic frequencies to fragment tissue then gently vacuum it out without affecting nearby vital structures.

The surgery was a success, and Lopez was discharged from Eisenhower just a few days later. He and his wife stayed in the area while he recuperated. But Lopez's journey back to health, and return to Idaho, took a few more twists and turns.

"I started getting goofy," Lopez says. "We found out that the fluid from my spine was coming up into my brain and wasn't draining properly."

"Once the tumor was removed, Mr. Lopez's brain had a hard time clearing cerebrospinal fluid because the protein content of the tumor had obstructed the filter through which the CSF circulates," Dr. Limonadi explains. (CSF is a clear fluid that surrounds the brain and spinal cord, acting as a protective cushion). This caused a condition called hydrocephalus, often referred to as "excessive water in the brain."

After a series of lumbar punctures (sometimes called a spinal tap) to draw off CSF and measure its protein levels, Lopez went back into the operating room about a month after his tumor was removed. Dr. Limonadi placed a shunt to divert the CSF in his brain, allowing it to reach a normal level.

Discharged from the hospital again in early August, Lopez and his wife planned to return to Idaho in September. But it wasn't meant to be.

"I got out of bed one night to use the bathroom, slipped and hit my head on the side where I'd had the operation," Lopez relates. "The next thing I know, I'm back in the hospital with a subdural hematoma (bleeding in the brain), and Dr. Limonadi had to operate on me again." This was late August.

A follow-up CT scan revealed that Lopez's subdural hematoma had started bleeding again — likely related to his platelet disorder. On September 26, he underwent a second surgery, at which time the shunt was "turned off" since his CSF levels had normalized.

Then, in early October, he had a stroke. "About two weeks after his second subdural hematoma surgery, I noticed that my husband just wasn't right," Donna Lopez says. "He was using his right hand to hold his fork and avoided using his left. I took him back to Eisenhower where he had another CT, which showed he'd had a minor stroke. It was too late to do anything about it, and it essentially resolved itself."

Finally, on October 26, Lopez's extraordinary run of health problems ended, and he was well enough to return home to Idaho. Dr. Limonadi wanted to see him for a follow-up visit in one year.

"He said that when I came back, and if he thought I was well, we'd go shooting to see how I was doing," Lopez recalls. "So this past September, after he looked me over in his office, he picked me up at my daughter's house and we went to a range."

"I figure if the surgeon who cut my head open is willing to stand there with me, he's got to be pretty happy with how things turned out," Lopez says.

"That he took the time to do such a personal thing and take my father shooting — that was above and beyond," Effinger says. "But he loved seeing that his work preserved my father's eyesight so he could continue to do something he loved." Lopez is certainly pleased.

"About three weeks ago, I went to my general practitioner for a physical," Lopez relates, "and he said 'this is the first time in a good long time that you're back to where you were before all this stuff happened to you. You're like your normal self, busy like you were.'"

And Lopez is busy indeed. He has resumed fine leatherworking, an avocation in which he had lost interest when his brain tumor was first diagnosed. He is also back to skeet and trap shooting, and he worked all last summer clearing trees in the woods around his Idaho home. He is also looking forward to attending the annual Los Angeles County Sheriff's Department (LASD) Retiree Roundup in Laughlin, Nevada in April (Lopez retired from the LASD in 1998 after 29 years of service).

"I'm so glad I work here at Eisenhower and got to know Dr. Limonadi," Effinger says. "Thanks to him, I got my father back, and his wife got her husband back."



#### Farhad Limonadi, MD on Delivering Excellent Patient Care

"We are a team of neurosurgeons and neurologists who work together in a coordinated and harmonious way," says Neurosurgeon Farhad Limonadi, MD, talking about the Eisenhower Neuroscience Institute. "As neurosurgeons, we cover all aspects of spinal care, from simple to complex to minimally invasive operations of the spinal cord as well as for brain pathologies."

"We have multiple multidisciplinary meetings at which we review each patient case and make treatment decisions together," he continues, referring to a weekly case conference to review back and neck problems, a biweekly brain tumor board (which also includes radiation oncologists, medical oncologists and primary care physicians), and monthly neuroscience collaborative meetings that review patient care for all spine, back, neck, stroke, vascular and tumor cases.

"To provide excellent patient care you must have a full understanding of the pathology and nature of the disease, understanding of the patient and their needs, be armed with knowledge of the best treatment plan for the individual patient, have the best technology and tools available, and be deliberate and able to make decisions appropriately and in a multidisciplinary fashion with checks and balances," Dr. Limonadi adds. "That's what we have at the Eisenhower Neuroscience Institute, thanks to our physicians and nurses, as well as administrators who provide us with the tools we need and who make patient care the number one priority."